

Topical Oxygen Emulsion

A Novel Wound Therapy

Stephen C. Davis, BS; Alejandro L. Cazzaniga, BS; Carlos Ricotti, MD; Paul Zalesky, PhD; Li-Chien Hsu, PhD; Jeffrey Creech, PhD; William H. Eaglstein, MD; Patricia M. Mertz, BA

Objective: To investigate the use of a topical oxygen emulsion (TOE), consisting of a supersaturated oxygen suspension using perfluorocarbon components, on second-degree burns and partial-thickness wounds.

Design: Oxygen is a required substance for various aspects of wound repair, and increased oxygen tension in a wound has been shown to stimulate phagocytosis and to reduce the incidence of wound infection. Second-degree burns and partial-thickness wounds were created on the backs of specific pathogen-free pigs. Wounds were then randomly assigned to 1 of the following treatment groups: TOE, TOE vehicle, or air-exposed control.

Main Outcome Measure: Wounds were assessed for complete epithelialization using a salt-split technique.

Results: The TOE was able to significantly ($P = .001$) enhance the rate of epithelialization compared with both vehicle and untreated control. These data suggest that topical oxygen may be beneficial for acute and burn wounds.

Conclusions: The results obtained from this double-blind, control, in vivo study demonstrate that TOE can significantly enhance the rate of epithelialization of partial-thickness excisional wounds and second-degree burns. These findings could have considerable clinical implications for patients with surgical and burn wounds by providing functional skin at an earlier date to act as a barrier against environmental factors, such as bacteria invasion. Other types of wounds may also benefit from this therapy (eg, chronic wounds and surgical incisions). Additional studies, including clinical studies, are warranted.

Arch Dermatol. 2007;143(10):1252-1256

A CONSTANT AND ADEQUATE oxygen supply is important for cell and tissue homeostasis. It is well documented that oxygen can play a key role in energy production, cell membrane maintenance, mitochondrial function, and cellular repair. Physical injury to skin can compromise the arterial, venous, or capillary systems of tissue, which in turn may cause hypoxia and ischemia.



CME available online at
www.archdermatol.com

The tissue repair process requires an increased metabolic activity of a variety of cells, resulting in a high oxygen demand.^{1,2} Recent research has demonstrated that increased oxygen tension in a wound promotes wound healing by stimulating several processes, including phagocytosis (engulfing of microorganisms, cells, or debris by macrophages or neutrophils),³ degradation of necrotic wound tissue,⁴ collagen production,⁵⁻⁷ neovascularization,^{8,9} and neutrophil-mediated oxidative microbial killing.¹⁰

Many different treatment modalities have been attempted to increase local oxy-

gen supply to wounds to accelerate repair. One potentially successful method is hyperbaric oxygen (HBO) therapy, which is somewhat controversial because studies have shown positive and neutral effects. Clinical research¹¹⁻¹⁶ has demonstrated that HBO therapy accelerates reepithelialization of chronic leg ulcers. Although HBO therapy can be effectively applied to treat wounds, especially in hypoxic tissues, HBO is not always practical or readily available, and can be relatively costly.

After treatment with HBO therapy, fibroblasts, an essential component of skin repair, show a dose-dependent increase in cellular proliferation. Fibroblasts cannot synthesize collagen in the absence of molecular oxygen, which is required for the hydroxylation of proline and lysine residues in the nascent procollagen molecule.¹⁷ Hyperbaric oxygen therapy depends on the lungs to increase the oxygen tension in the blood, which is then transported systemically throughout the body and finally to the wound.

Topical application of gaseous oxygen, at normal or elevated partial pressures, to skin wounds and ischemic lesions has been attempted; however, as a gas, oxygen has

Author Affiliations:

Department of Dermatology & Cutaneous Surgery, University of Miami School of Medicine, Miami, Florida (Messrs Davis and Cazzaniga, Drs Ricotti and Eaglstein, and Ms Mertz); and TherOx Inc, Irvine, California (Drs Zalesky, Hsu, and Creech).

limited ability to penetrate the skin. On exposure to atmospheric pressures, oxygen microbubbles nucleate, coalesce, and effervesce from the topical preparation, thereby reducing the oxygen content to ambient levels. Peroxide-containing formulations have been developed, some of which are available commercially. These formulations can provide small quantities of oxygen to tissues by either spontaneous breakdown or enzymatic breakdown following tissue contact. Peroxide formulations are mildly bactericidal and are used primarily to remove dirt and debris from acute traumatic lesions. Unfortunately, peroxides are irritating to raw tissue, have limited capacity to support metabolic oxygen requirements, and are believed to delay wound healing, thus limiting their use as wound-promoting agents.

The ideal topical oxygen agent would provide sufficient quantities of oxygen to a wound several hours after application and be nontoxic to the skin to accelerate local tissue repair. TherOx Inc has developed a technique by which an emulsion-containing supersaturated oxygen can be delivered topically to a wound, where it can slowly release additional oxygen over time. This technology is based on perfluorocarbon droplets being encapsulated within an aqueous continuous phase. The oxygen solubility of the perfluorocarbon is relatively high (approximately 20 times greater than water); therefore, it has a high oxygen-carrying capacity. Oxygen is dissolved into the perfluorocarbon emulsion and stored under pressure in a small dispensing bottle. By maintaining pressure on the emulsion, dissolution and outgassing are prevented during storage and the maximum oxygen concentration is delivered on dispensation. The topical cream is formulated with biocompatible emulsifying agents to ensure adequate stability of the dispersed perfluorocarbon droplets. Before dispensation, the dissolved oxygen concentration contained in the topical emulsion is approximately 2.0 mL of oxygen (standard temperature and pressure) per milliliter of emulsion.

Herein, we report the use of a novel topical oxygen emulsion (TOE) that promoted wound healing of second-degree burns and partial-thickness wounds.

METHODS

EXPERIMENTAL ANIMALS

Pigs were used as our experimental animal because they have skin that is anatomically and physiologically similar to humans and are considered an excellent tool for the evaluation of therapeutic agents. There is a strong correlation between pig and human wound-healing studies.¹⁸ Sixteen pigs were used for these studies (8 for partial-thickness wounds and 8 for second-degree burns) using well-defined porcine models.¹⁹⁻²⁴ The animal protocol used for this study was approved by the University of Miami Institutional Animal Care and Use Committee. Animals were monitored daily, and to help minimize possible discomfort, an analgesic, buprenorphine, 0.03 mg/kg, was given to each animal the first day while under anesthesia and a transdermal agent (fentanyl [Duragesic]), 25 µg/h, was used during the entire experiment.

WOUNDING TECHNIQUE

Three grids were outlined on the dorsum and flanks of each pig. For the partial-thickness wounds, the injuries

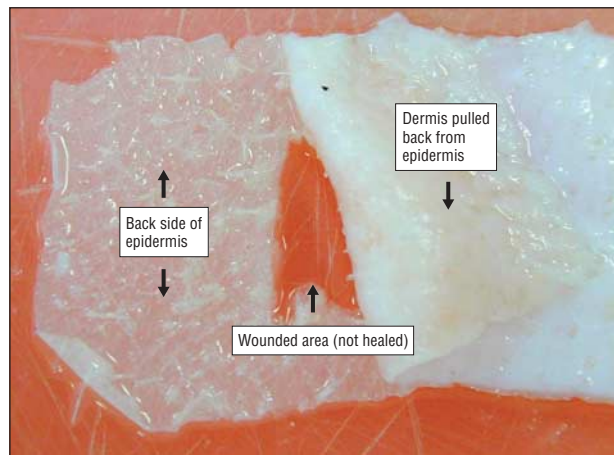


Figure 1. Epidermal migration assessment (nonhealed wound).

(0.7 × 10.0 × 0.3 mm) were made with an electrokeratome. A total of 120 partial-thickness wounds were created on each pig.

The burn wounds were made using the following method. Five specially designed cylindrical brass rods weighing 358 g each were heated in a boiling water bath to 100°C. A rod was removed from the water bath and wiped dry before it was applied to the skin surface to prevent water droplets from creating a steam burn on the skin. The brass rod was held at a vertical position on the skin (6 seconds), with all pressure supplied by gravity, to make a burn wound 8.5 mm in diameter by 0.8 mm deep. Again, 120 burn wounds were made on the anterior two-thirds of the animal. Burn wounds and partial-thickness wounds were randomly assigned to 1 of the following treatment groups according to the following experimental design.

TREATMENTS AND EXPERIMENTAL DESIGN

Treatments (active TOE containing oxygen, vehicle without oxygen, or untreated air exposed) were randomly assigned to the wounds. The treatments were given to the investigators in a blinded fashion (pressurized containers labeled A and B). Wounds were treated twice daily for the first 5 days and once thereafter until all wounds were 100% completely reepithelialized. Treatments were covered with a secondary dressing (Release nonadherent gauze) and secured in place with Coban self-wrapping bandages. The experimental design for both the partial-thickness study and the second-degree burn study included 8 animals, with 120 wounds per animal (for a total of 960 wounds), 40 wounds per treatment group.

EPIDERMAL MIGRATION ASSESSMENT

The partial-thickness wounds were assessed on days 3 to 9 after wounding (day 0), and the second-degree burns were assessed on days 7 to 14 after burning. Beginning on the first assessment day and on each day thereafter until all wounds were 100% reepithelialized, 5 wounds and surrounding normal skin from each treatment group were excised using a standard-width (22 mm) electrokeratome blade set at a depth of 0.5 mm. Specimens that were not excised intact were discarded. Excised skin containing the wound site was incubated in 0.5M sodium bromide at 37°C for 24 hours, allowing for a separation of the dermis from the epidermis²⁵ (**Figure 1**). After the separation, the epidermal sheet was examined macroscopically for defects. Defects were defined as holes in the epidermal sheet in the area of the wound. Reepithelialization is considered complete if no defects were present; any defect in the wound area indicates that healing was incomplete, and if no defects were seen, the wound is considered




Figure 2. Example of a healed wound.

completely epithelialized or healed (**Figure 2**). The epidermis must be fairly mature (at least 5-7 cell layers) to withstand the separation technique. The number of completely healed (reepithelialized) wounds was then divided by the number of wounds assessed. This gives a percentage of wounds that are completely reepithelialized (eg, on day 8, $[12/40] \times 100\% = 30\%$ of wounds completely reepithelialized).

STATISTICAL ANALYSES

After the study is completed, the number of wounds healed (completely epithelialized) will be divided by the total number of wounds sampled per day and multiplied by 100. The percentage of wounds will be plotted against days after wounding. Analysis by χ^2 4-fold tables was performed on the combined data to determine any treatment response.

RESULTS

For the partial-thickness wound study, the wound that received the TOE had a significantly enhanced rate of epithelialization compared with the vehicle and untreated air-exposed wounds (on days 4, 5, and 6). In the second-degree burn study, the TOE also had a significantly enhanced rate of epithelialization compared with vehicle and untreated burn control wounds (on days 7, 8, and 9 after the burn) (**Table 1** and **Table 2**). The vehicle also showed a significant increase in epithelialization when compared with untreated control wounds (for partial-thickness wounds, on days 5, 6, and 7; and for second-degree burn wounds, on days 10, 11, and 12).

COMMENT

Following tissue injury, several wound repair mechanisms are sequentially activated. These activities are grouped into the 3 overlapping phases of wound healing: inflammation, proliferation, and remodeling. All physiologically active processes involved in these phases are in need of an adequate supply of oxygen.

After the initial trauma, there is vascular damage followed by hemostatic mechanisms to prevent blood loss. Coagulation and vasoconstriction are physiologic mechanisms of hemostasis in the wound. Oxygen delivery via the

vasculature to the wound at this stage is compromised. The oxygen supply is limited, and delivery to the wound is dependent on diffusion from the surrounding tissue and atmosphere. In normal wound healing, the decrease in oxygen supply is transient. Schweiki et al²⁶ demonstrated in vitro that hypoxia leads to an increase in translation of vascular endothelial growth factor. This increase in vascular endothelial growth factor stimulates angiogenesis, resulting in the reestablishment of the vascular network in the wound bed.²⁷ Interestingly, for the endothelium to be maximally responsive to vascular endothelial growth factor, it must first sense hypoxia.²⁶ Hypoxic environments also increase collagen production by fibroblasts and promote fibroblast proliferation.²⁸ These cellular processes (angiogenesis, collagen production, and cell proliferation) are part of normal tissue and cellular adaptation when their normal environment changes. For normal wound healing, the initial hypoxic environment may promote the healing process; however, long-term hypoxia impedes wound healing, and oxygen delivery would be beneficial.

Over time, the result of an increase in oxygen demand by leukocytes and fibroblasts and a reduced oxygen supply in a wound leads to anaerobic metabolism. Extended anaerobic metabolism leads to an increase in metabolites and a lack of energy production. Inadequate cell energy levels impair protein production and cell homeostasis. At the same time, vascular compromise and loss of blood flow disable the tissue from eliminating metabolites, such as lactic acid, from the wound.²⁹ Lactic acid, a byproduct of anaerobic metabolism, accumulates and acidifies the wound environment, which may lead to cell death. Long-term hypoxia and loss of the ability for cells to adapt to hypoxia lead to impaired and pathologic wound healing. Research has focused on increasing oxygen supply to hypoxic and ischemic tissues to promote wound healing.

The administration of external supplemental oxygen may help in the wound healing process by providing ischemic tissue cells with the required oxygen tension needed to survive and proliferate, especially in the situation of extended oxygen limitation.³⁰ When the new vasculature is well established and oxygen molecules can reach the repairing cells by diffusing throughout the new blood vessels, therapies such as HBO may prove to be effective. In addition to the direct effects of oxygen in wound healing and cellular repair, the role of oxygen in controlling infections has been examined. The open wound bed is a fertile breeding ground for a broad variety of pathogenic microorganisms. Wounds that are well perfused and oxygenated have been shown to be less likely to become infected.^{31,32}

Systemic HBO therapies entail the inhalation of 100% oxygen under pressures between 2 and 3 atmospheric pressure. The high pressure, in addition to the high levels of oxygen, considerably increases the dissolved oxygen levels into blood plasma. This therapeutic approach is indicated to treat acute traumatic ischemias, necrotizing fasciitis, irradiated tissues, refractory osteomyelitis,³³ and certain chronic wound conditions.³⁴ However, as previously mentioned, HBO therapies are effective if the vascular network is functional in the wounded tissues. Hyperbaric oxygen may not be effective on ischemic chronic leg ulcers and superficial burns. In addition to the limited research of these therapies on various types

Table 1. Partial-Thickness Epithelialization Results

Treatment	Time After Wounding, d ^a						
	3	4	5	6	7	8	9
Active	0/40	18/40 (45)	34/40 (85)	40/40 (100)	40/40 (100)	40/40 (100)	40/40 (100)
Vehicle	0/40	4/40 (10)	15/40 (38)	29/40 (72)	40/40 (100)	40/40 (100)	40/40 (100)
Untreated	0/40	0/40	0/40	3/40 (8)	25/40 (62)	40/40 (100)	40/40 (100)

^aData are given as number of wounds completely epithelialized/total number of wounds assessed (percentage). On days 4 and 5, $P < .001$ for the active group vs the vehicle and untreated groups; on day 5, $P < .001$ for the vehicle group vs the untreated group; on day 6, $P < .001$ for the active group vs the vehicle and untreated groups and for the vehicle group vs the untreated group; and on day 7, $P < .001$ for the active and vehicle groups vs the untreated group.

Table 2. Second-degree Burn Epithelialization Results

Treatment	Time After the Burn, d ^a							
	7	8	9	10	11	12	13	14
Active	9/40 (22)	28/40 (70)	37/40 (92)	40/40 (100)	40/40 (100)	40/40 (100)	40/40 (100)	40/40 (100)
Vehicle	0/40	13/40 (32)	28/40 (70)	38/40 (95)	40/40 (100)	40/40 (100)	40/40 (100)	40/40 (100)
Untreated	0/40	0/40	3/40 (8)	10/40 (25)	22/40 (55)	31/40 (78)	35/40 (88)	40/40 (100)

^aData are given as number of burns completely epithelialized/total number of wounds assessed (percentage). On days 7 and 8, $P < .001$ for the active group vs the vehicle and untreated groups; on day 9, $P < .02$ for the active group vs the vehicle group and $P < .001$ for the active group vs the untreated group; on days 10 and 11, $P < .001$ for the active and vehicle groups vs the untreated group; and on day 12, $P < .01$ for the active and vehicle groups vs the untreated group.

of wounds, these hyperbaric therapies require the use of large and cumbersome machinery. This inconvenience limits their widespread use in the clinical setting and their potential use for the military on the battlefield.

Topical HBO therapy is oxygen delivered at slightly increased atmospheric pressures directly to the surface of the wound. The name HBO therapy implies that pressures used in treatment are greater than 1 atm. Because "topical" HBO therapy is applied at pressures barely over 1 atm, the use of the term *topical hyperbaric therapy* is not only misleading but a misnomer. One should be wary of any so-called topical hyperbaric therapies that make various healing and/or rejuvenation claims, especially when few or no data are available to support their use. Hyperbaric oxygen is becoming a more accepted treatment modality, especially as an adjunctive therapy, because of the increase in studies showing potential mechanisms of action. Heng et al³⁵ compared topical HBO therapy with the standard of treatment for necrotic gangrenous wounds that lack blood supply. Forty patients were included in the study, and 90% of patient ulcers that received topical HBO healed compared with 25% of patient ulcers treated with standard wound management therapy. No oxygen reperfusion damage was noted. The group also demonstrated that the topical HBO-treated ulcers had an increase in angiogenesis in the wound bed.

One appealing method for oxygen treatment is topical delivery. Many different topical oxygen delivery systems have been attempted for wound healing, but unfortunately most of these therapies have yielded poor results. One of the major criticisms of topical oxygen therapies is the inadequate delivery of oxygen deep into the skin to provide fibroblasts, keratinocytes, and inflammatory cells increased oxygen required for repair. Recent advancements have allowed the creation of a hy-

peroxygenated emulsion for topical delivery of oxygen to wounds. Unpublished ex vivo assays performed by our group determined that our hyperoxygenated emulsion consistently increased subcutaneous oxygen tension when compared with vehicle and phosphate-buffered solution. The treated viable tissue also demonstrated an initial peak in PO_2 levels with a decrease over time. Treated nonviable tissue results show an increase in PO_2 levels without the decrease over time. This suggests that the cells in the viable tissue may be using the supplied oxygen from the topical emulsion in metabolic pathways. Once we established that the vehicle was able to carry the oxygen deep into skin, we set out to study this TOE on wounds. The fact that the vehicle also enhanced the rate of epithelialization in the porcine wound models is not surprising because it has previously been shown that vehicles are not inert and can either adversely or beneficially affect the healing process.³⁶ In both of these studies (burns and acute partial-thickness wounds), we found the TOE to have a significant effect over vehicle alone.

Interestingly, the use of a TOE not only stimulated epithelialization of ischemic second-degree burns but also of well-vascularized acute wounds. Using the same porcine models, we have also evaluated possible mechanisms of topical oxygen and found an up-regulation of vascular endothelial growth factor, collagens I and III, and matrix metalloproteinase levels after treatment with the TOE. These findings will be the subject of a subsequent article that will document possible mechanisms of this therapy. Although hypoxia and hypoxemia have been shown to influence either keratinocyte proliferation or differentiation and collagen synthesis in vitro.^{28,37,38} These studies simply suggest that an external factor, such as low oxygen levels, which may be present during tissue repair, can influence various specific cellular processes. Purposefully in-

ducing hypoxic environments to wounds clinically would most likely lead to necrosis and impaired healing.

The results obtained from this double-blind, control, in vivo study demonstrate that the TOE can significantly enhance epithelialization of partial-thickness acute wounds and second-degree burns. We believe that the oxygen supplied by the emulsion to the wound environment directly promotes cellular repair and the local immune response to speed wound healing. Our findings may have important clinical implications for patients with wounds by providing functional skin at an earlier date to act as a barrier against environmental factors, such as water loss and bacteria invasion. Other types of wounds may also benefit from this therapy (eg, ischemic and chronic wounds), and more studies, including clinical studies, are warranted.

Accepted for Publication: May 15, 2007.

Correspondence: Stephen C. Davis, BS, Department of Dermatology & Cutaneous Surgery, University of Miami School of Medicine, 1600 NW 10th Ave, Room 2089, Miami, FL 33136 (SDavis@med.miami.edu).

Author Contributions: Mr Davis had full access to all the data in the study and takes responsibility for the integrity of the data and the accuracy of the data analysis. *Study concept and design:* Davis, Ricotti, Zalesky, Hsu, Creech, and Mertz. *Acquisition of data:* Davis, Cazzaniga, Ricotti, Hsu, and Mertz. *Analysis and interpretation of data:* Davis, Cazzaniga, Ricotti, Eaglstein, and Mertz. *Drafting of the manuscript:* Davis, Ricotti, and Creech. *Critical revision of the manuscript for important intellectual content:* Davis, Cazzaniga, Ricotti, Zalesky, Hsu, Eaglstein, and Mertz. *Statistical analysis:* Ricotti. *Obtained funding:* Davis, Ricotti, Hsu, and Mertz. *Administrative, technical, and material support:* Davis, Cazzaniga, Hsu, and Creech. *Study supervision:* Davis, Zalesky, Eaglstein, and Mertz.

Financial Disclosure: None reported.

Funding/Support: This study was supported by a small business innovative research grant from TherOx Inc/Defense Advanced Research Projects Agency.

Role of the Sponsor: The funding bodies had no role in the design and conduct of the study and in the collection, analysis, and interpretation of the data; however, they did help review the final manuscript and gave some background information regarding the test article.

Additional Contributions: Kurt Henry, MD, LCDR (US Navy), and Matt Healy, PhD (Booze Allen Hamilton Inc), provided help and support with this project.

REFERENCES

- LaVan FB, Hunt TK. Oxygen and wound healing. *Clin Plast Surg*. 1990;17(3):463-470.
- Niinikoski J, Hunt TK, Dunphy JE. Oxygen supply in healing tissue. *Am J Surg*. 1972;123(3):247-252.
- Hohn DC, MacKay RD, Halliday B, Hunt TK. The effect of O₂. *Surg Forum*. 1976;27(62):18-20.
- Dalton SJ, Whiting CV, Bailey JR, Mitchell DC, Tarlton JF. Mechanism of chronic skin ulceration linking lactate, transforming growth factor- β , vascular endothelial growth factor, collagen remodeling, collagen stability, and defective angiogenesis. *J Invest Dermatol*. 2007;127(4):958-968.
- Niinikoski J. Effect of oxygen supply on wound healing and formation of experimental granulation tissue. *Acta Physiol Scand Suppl*. 1969;334:1-72.
- Hunt TK, Pai MP. The effect of varying ambient oxygen tensions on wound metabolism and collagen synthesis. *Surg Gynecol Obstet*. 1972;135(4):561-567.
- Hsu RW, Hsu WH, Tai CL, Lee KF. Effect of hyperbaric oxygen therapy on patellar tendinopathy in a rabbit model. *J Trauma*. 2004;57(5):1060-1064.
- Meltzer T, Myers B. The effect of hyperbaric oxygen on the bursting strength and the rate of vascularization of skin wounds in the rat. *Am Surg*. 1986;52(12):659-662.
- Knighton DR, Silver IA, Hunt TK. Regulation of wound-healing angiogenesis. *Surgery*. 1981;90(2):262-270.
- Mader JT, Brown GL, Guckian JC, Reinartz JA. A mechanism for the amelioration by hyperbaric oxygen of experimental staphylococcal osteomyelitis in rabbits. *J Infect Dis*. 1980;142(6):915-922.
- Cianci P, Hunt TK. Adjunctive hyperbaric oxygen therapy in treatment of diabetic foot wounds. In: Levin ME, O'Neal LW, Bowker JH, eds. *The Diabetic Foot*. 5th ed. St Louis, MO: Mosby-Year Book Inc; 1993:305-319.
- Hammarlund C, Sundberg T. Hyperbaric oxygen reduced size of chronic leg ulcers: a randomized double-blind study. *Plast Reconstr Surg*. 1994;93(4):829-833.
- Doctor N, Pandya S, Supe A. Hyperbaric oxygen therapy in diabetic foot. *J Postgrad Med*. 1992;38(3):112-114.
- Cianci P. Advances in the treatment of the diabetic foot: is there a role for adjunctive hyperbaric oxygen therapy? *Wound Repair Regen*. 2004;12(1):2-10.
- Stone J, Cianci P. The adjunctive role of hyperbaric oxygen therapy in the treatment of lower extremity wounds in patients with diabetes. *Diabetes Spectrum*. 1997;10:118-123.
- Fife CE, Buyukcakil C, Otto G, Sheffield P, Love T, Warriner R. Factors influencing the outcome of lower-extremity diabetic ulcers treated with hyperbaric oxygen therapy. *Wound Repair Regen*. 2007;15(3):322-331.
- Jeffrey JJ. Collagen degradation. In: Cohen IK, Diegelmann RF, Lindblad WJ, eds. *Wound Healing: Biochemical and Clinical Aspects*. Philadelphia, PA: WB Saunders Co; 1992:177-194.
- Sullivan TP, Eaglstein WH, Davis SC, Mertz PM. The pig as a model for human wound healing. *Wound Repair Regen*. 2001;9(2):66-76.
- Eaglstein WH, Davis SC, Mehle AL, Mertz PM. Optimal use of an occlusive dressing to enhance healing. *Arch Dermatol*. 1988;124(3):392-395.
- Sauder DN, Kilian PL, McLane JA, et al. Interleukin-1 enhances epidermal wound healing. *Lymphokine Res*. 1990;9(4):465-473.
- Mertz PM, Davis SC, Franzén L, et al. Effect of an RGD peptide-containing artificial matrix on epithelial sheet migration and experimental second-degree burn wound healing. *J Burn Care Rehabil*. 1996;17(3):199-206.
- Davis SC, Bilevich ED, Cazzaniga AL, Mertz PM. Early debridement of second-degree burn wounds enhances the rate of epithelialization: an animal model to evaluate burn wound therapies. *J Burn Care Rehabil*. 1996;17(6, pt 1):558-561.
- Davis SC, Eaglstein WH, Cazzaniga AL, Mertz PM. An octyl-2-canoacrylate formulation speeds healing of partial thickness wounds. *Dermatol Surg*. 2001;27(9):783-788.
- Davis SC, Mertz PM, Eaglstein WH. Second-degree burn healing: the effect of occlusive dressings and a cream. *J Surg Res*. 1990;48(3):245-248.
- Eaglstein WH, Mertz PM. New method for assessing epidermal wound healing. *J Invest Dermatol*. 1978;71(6):382-384.
- Shweiki D, Itin A, Soffer D, Keshet E. Vascular endothelial growth factor induced by hypoxia may mediate hypoxia-initiated angiogenesis. *Nature*. 1992;359(6398):843-845.
- Li J, Zhang YP, Kirsner R. Angiogenesis in wound repair: angiogenic growth factors and the extracellular matrix. *Microsc Res Tech*. 2003;60(1):107-114.
- Falanga V, Zhou L, Yufit T. Low oxygen tension stimulates collagen synthesis and COL1A1 transcription through the action of TGF- β 1. *J Cell Physiol*. 2002;191(1):42-50.
- Zamboni WA, Browder LK, Martinez J. Hyperbaric oxygen and wound healing. *Clin Plast Surg*. 2003;30(1):67-75.
- Marx RE, Ehler WJ, Tayapongsak P, Pierce LW. Relationship of oxygen dose to angiogenesis induction in irradiated tissue. *Am J Surg*. 1990;160(5):519-524.
- Kurz A, Sessler DI, Lenhardt R. Perioperative normothermia to reduce the incidence of surgical-wound infection and shorten hospitalization: Study of Wound Infection and Temperature Group. *N Engl J Med*. 1996;334(19):1209-1215.
- Hopf HW, Hunt TK, West JM, et al. Wound tissue oxygen tension predicts the risk of wound infection in surgical patients. *Arch Surg*. 1997;132(9):997-1004.
- Strauss MB. Refractory osteomyelitis. *J Hyperbar Med*. 1987;2:146-159.
- Grim PS, Gottlieb LJ, Boddie A, Batson E. Hyperbaric oxygen therapy. *JAMA*. 1990;263(16):2216-2220.
- Heng MC, Harker J, Csathy G, et al. Angiogenesis in necrotic ulcers treated with hyperbaric oxygen. *Ostomy Wound Manage*. 2000;46(9):18-28, 30-32.
- Eaglstein WH, Mertz PM. "Inert" vehicles do affect wound healing. *J Invest Dermatol*. 1980;74(2):90-91.
- Dimitrijevic SD, Paranjape S, Wilson JR, Gracy RW, Mills JG. Effect of hyperbaric oxygen on human skin cells in culture and in human dermal and skin equivalents. *Wound Repair Regen*. 1999;7(1):53-64.
- Hollander DA, Hakimi MY, Hartmann A, Wilhelm K, Windolf J. The influence of hyperbaric oxygenation (HBO) on proliferation and differentiation of human keratinocyte cultures in vitro. *Cell Tissue Bank*. 2000;1(4):261-269.